FIBROCALCULOUS PANCREATIC DIABETES IN THE ELDERLY

V Mohan*, S Suresh**, Indrani Suresh**, A Ramachandran*, S Ramakrishnan*, C Snehalatha*, M Viswanathan*

SUMMARY:

Fibrocalculous pancreatic diabetes (FCPD) is a form of diabetes seen in tropical countries. It is secondary to chronic, calcific, non-alcoholic pancreatitis. FCPD is usually a disease of youth. This paper reports on two elderly onset cases of FCPD. Macrovascular complications are usually rare in FCPD patients. These two patients had evidence of macrovascular diseases probably due to the older age group of the patients.

Key Words: Diabetic-Pancreatic-Fibrocalculous Pancreatitis-Macrovascular complications

INTRODUCTION

Fibrocalculous pancreatic diabetes (FCPD) is a form of diabetes specific to the tropical belt. It is characterized by diabetes secondary to chronic, calcific (nonalcoholic) pancreatitis. Earlier papers have reported the clinical profile of FCPD[1,2]. Recently, a lot of heterogeneity has been described in the presentation of FCPD[3]. FCPD has been always believed to be a disease which starts in childhood or adolescence. Late onset FCPD has been recognized less often. In Geevarghese's first 400 FCPD patients only one patient was reported to have diabetes with onset above 50 years of age. In this paper, we report on 2 patients with FCPD with late onset of the disease.

CASE REPORT

Mrs. VN a 64 year old lady was referred to our centre for control of diabetes. She was a resident of Madras but originally belonged to Kerala state. She had diabetes of 5 years duration. The diabetes was detected at the age of 59 years during investigation for polyuria and polydipsia. She had no family history of diabetes. She had history of recurrent abdominal pain and 'indigestion' for several years. She also gave history of passing bulky and oily stools. She had been treated with oral hypoglycaemic agents initially but due to lack of control of diabetes, insulin therapy was started. On examination she was found to be lean, weight 36.4 kg; height 146 cm; Body Mass Index: 17.0 kg/m^2. There were signs of protein calorie malnutrition. She was anaemic (Hb 10.2). Cardiovascular system showed evidence of a soft systolic murmur. BP was 200/110 mmHg. Other systems were within normal limits. Fundus examination by direct and indirect ophthalmoscopy did not reveal any evidence of diabetic retinopathy. GTT showed severe diabetes with fasting plasma glucose of 335 mg/dl and peak of 584 mg/dl. There was no ketonuria. Glycosylated haemoglobin was 12.1%. X-ray chest was normal.

*Diabetes Research Centre and M.V. Hospital for Diabetes 5, Main Road, Madras - 600 013.
**Mediscan Systems 11, Seshadri Road, Madras - 600 018.
Received: 16-7-1987
Accepted: 13-1-1989

X-ray abdomen showed evidence of a big calculus to the right of the L_1 vertebra corresponding to the region of the head of the pancreas (Fig 1). Real time ultrasonography was performed which showed evidence of chronic pancreatitis with increased echogenicity and multiple calculi in the pancreas. The pancreatic duct was dilated (Fig 2).

ECG showed evidence of lateral wall ischaemia. Kidney function tests and serum lipid profile were normal. She was treated with a combination of regular and intermediate acting insulins, enzyme replacement and antihypertensive drugs.

Fig. 1. Pancreatic calculi in the head region in a patient with elderly onset FCPD.

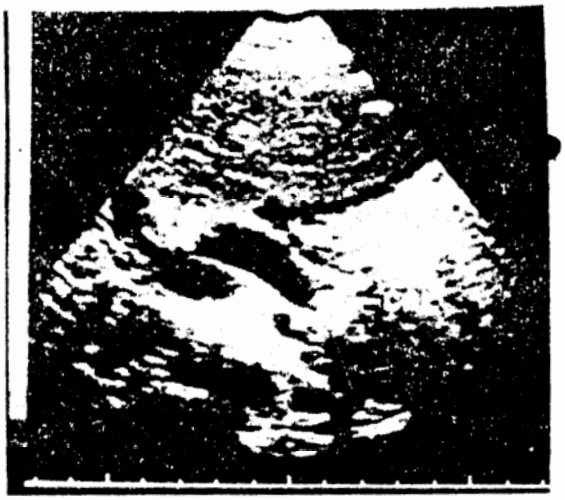

Fig. 2. Showing multiple calculi in the pancreas, dilated pancreatic duct and increased echogenicity of the pancreas.

Case 2:

Mrs. TG a 60 year old lady developed diabetes at the age of 50 years. She had been known to have chronic calcific relapsing pancreatitis for a few years prior to the onset of diabetes. She belonged to Tamil Nadu and had a positive family history of diabetes. She had severe diabetes with plasma glucose values persistently above 350 mg% but no acetonuria. The glycosylated haemoglobin was 10.1%. Her BMI was 19.6 Kg/m^2. X-ray abdomen showed evidence of multiple pancreatic calculi. The ultrasonogram showed evidence of fibrosis of the gland, with multiple pancreatic calculi. The pancreatic duct was dilated. Her BP was 100/80 mm with antihypertensive treatment. There was no evidence of retinopathy or nephropathy. The blood urea was 24 mg%, and serum creatinine 0.7 mg%. Lipid profile was normal. ECG showed evidence of infero-lateral ischaemia. The other investigations were within normal limits. She also required insulin for control of diabetes.

DISCUSSION:

This paper highlights the occurrence of FCPD at an older age group. FCPD is usually described as a disease of younger age group. In fact some authors have suggested onset at a younger age as a diagnostic criterion[4]. This report shows that FCPD can occur at any age group and hence age should not be used as a diagnostic criterion for FCPD.

In both cases, the onset of diabetes was several years after the occurrence of chronic pancreatitis. This plus the absence of family history of diabetes, the severe insulin requiring and yet ketosis resistant diabetes and other clinical features help to clinch the diagnosis of FCPD. Other causes of chronic pancreatitis such as alcoholism, gall stones etc. were excluded in both these patients. Nagai and Ohtsuba have shown that pancreatic calculi can occur in the elderly, due to the aging process[5]. However in their report, it is noteworthy that under the age of 69 years, the incidence of pancreatic calculi was 0% and it was 4.2% in the 70's, 7.7% in the 80's, 16.7% in the 90's. Both our patients developed calculi and diabetes under the age of 65 years and hence it is unlikely that calculi in these patients were the result of aging.

Another point of interest in this report is the occurrence of ischaemic heart disease in both patients, and hypertension in one patient. It was earlier believed that patients with FCPD are less prone to vascular complications[2]. We have recently shown that microvascular complications, namely, retinopathy, nephropathy and neuropathy occur in FCPD[3]. LV dysfunction also occurs in these patients[6]. However, we were unable to find evidence of macrovascular complications so far. This was attributed to the young age of the patients, leanness and low cholesterol levels[3]. This report shows that when FCPD occurs at an older age group, these pa-

..s are prone to macrovascular complications just like patients with primary form of diabetes.

REFERENCES

1. Geevarghese PJ. Pancreatic Diabetes. Bombay: Popular Prakasan, 1968.
2. Viswanathan M. Pancreatic Diabetes in India: an overview. In: Secondary Diabetes: the spectrum of diabetic syndromes. Podolsky S., Viswanathan M. Eds. New York: Raven Press, 1980: 105-16.
3. Mohan V, Mohan R, Susheela L, *et al.* Tropical pancreatic diabetes in S. India. Heterogeneity in clinical and biochemical profile. Diabetologia, 1985, 28:229-32.
4. MacMillan DE. Tropical malnutrition diabetes. Diabetologia, 1986, 28:708.
5. Nagai H, Ohtsuba K. Pancreatic lithiasis in the aged. Its clinicopathology and pathogenesis. Gastroenterology, 1984, 86:331-8.
6. Ramachandran A, Mohan V, Snehalatha C, *et al.* Left ventricular dysfunction in fibrocalcific pancreatic diabetes. Acta Diabetol. Latina, 1987, 24:81-2.